MARQUARDT Medizintechnik

FUNKTIONALE OBERFLÄCHEN VON IMPLANTATEN

MEDIZINTECHNISCHES KOLLOQUIUM

28.11.2019

MARQUARDT
Medizintechnik

MARQUARDT
Medizintechnik

DIFFERENZIERUNG

Dieter Marquardt Medizintechnik GmbH

- Gründung 1980
  - Entwicklung
  - Produktion
  - Vertrieb

- Implantatsysteme zur Osteosynthese

Osteosynthese

- Wiederherstellung nach Trauma oder Korrektur
- ca. 1,5 Millionen Knochenbrüche jährlich in Deutschland mit Schrauben und Platten fixiert
- Tuttlingen: **139.397** Einwohner → ca. **280** distale Radius Frakturen

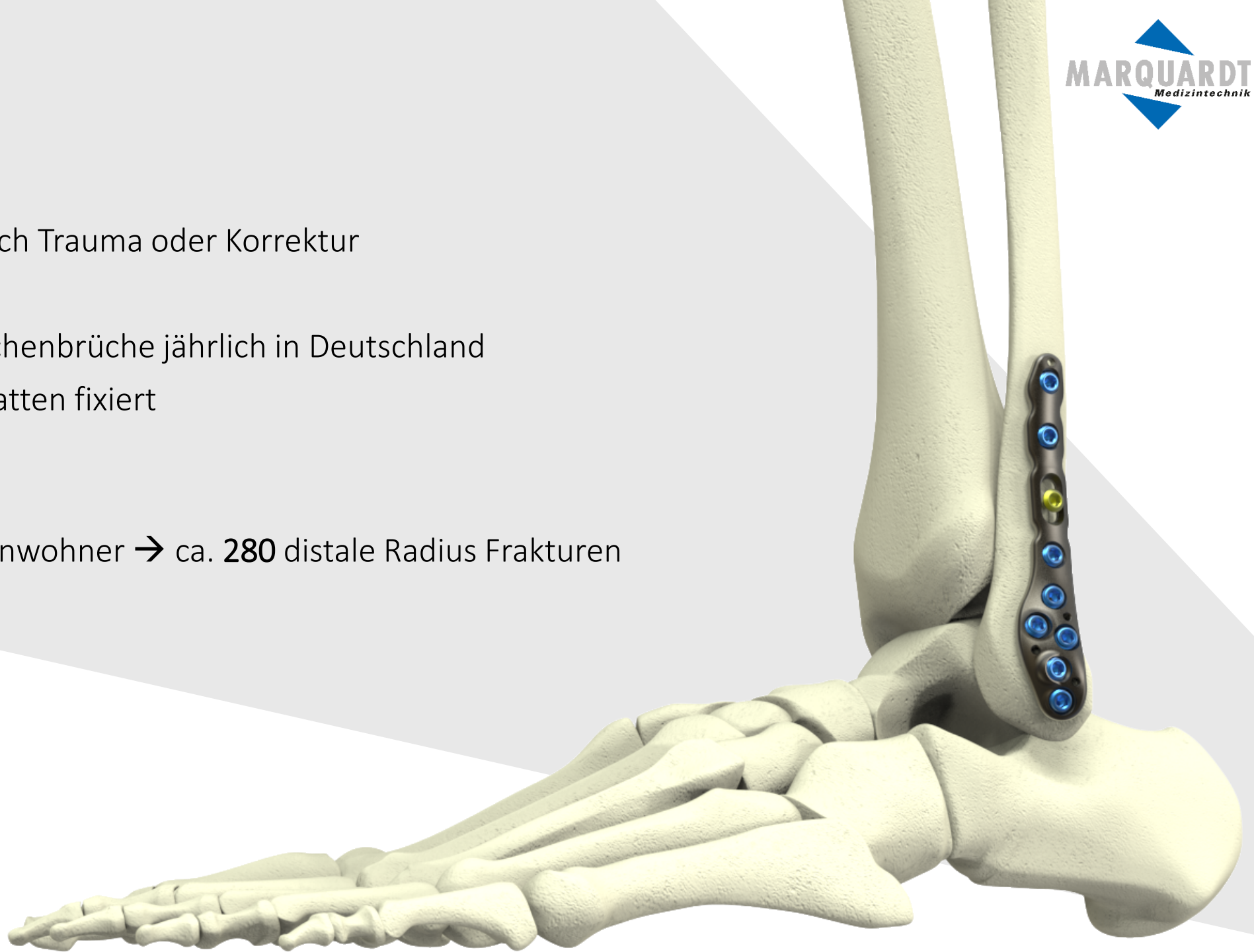

Oberflächenfunktionalisierung

Oberfläche

➔ Schnittstelle zwischen Implantat und Gewebe

- Informationsvermittlung
- Einwachsverhalten modifizieren → Osseointegration
- Biokompatibilität / Bioaktivität

Oberflächenfunktionalisierung

Verfahren

- Mechanisch - Physikalisch
- Chemisch - Biologisch
- Additiv / Subtraktiv

- Topographie
- Chemische Zusammensetzung

Oberflächenverfahren – Anodisieren Typ III

- Identifikation erleichtern

Spannung

↓

Schichtdicke (20 – 200 nm)

↓

Farbton

Oberflächenverfahren – Anodisieren Typ II

- Mikroporen und Risse abschwächen
- Ermüdungsfestigkeit + 15%
- Schichthärte + 25%

➔ Integration in Knochengewebe reduzieren

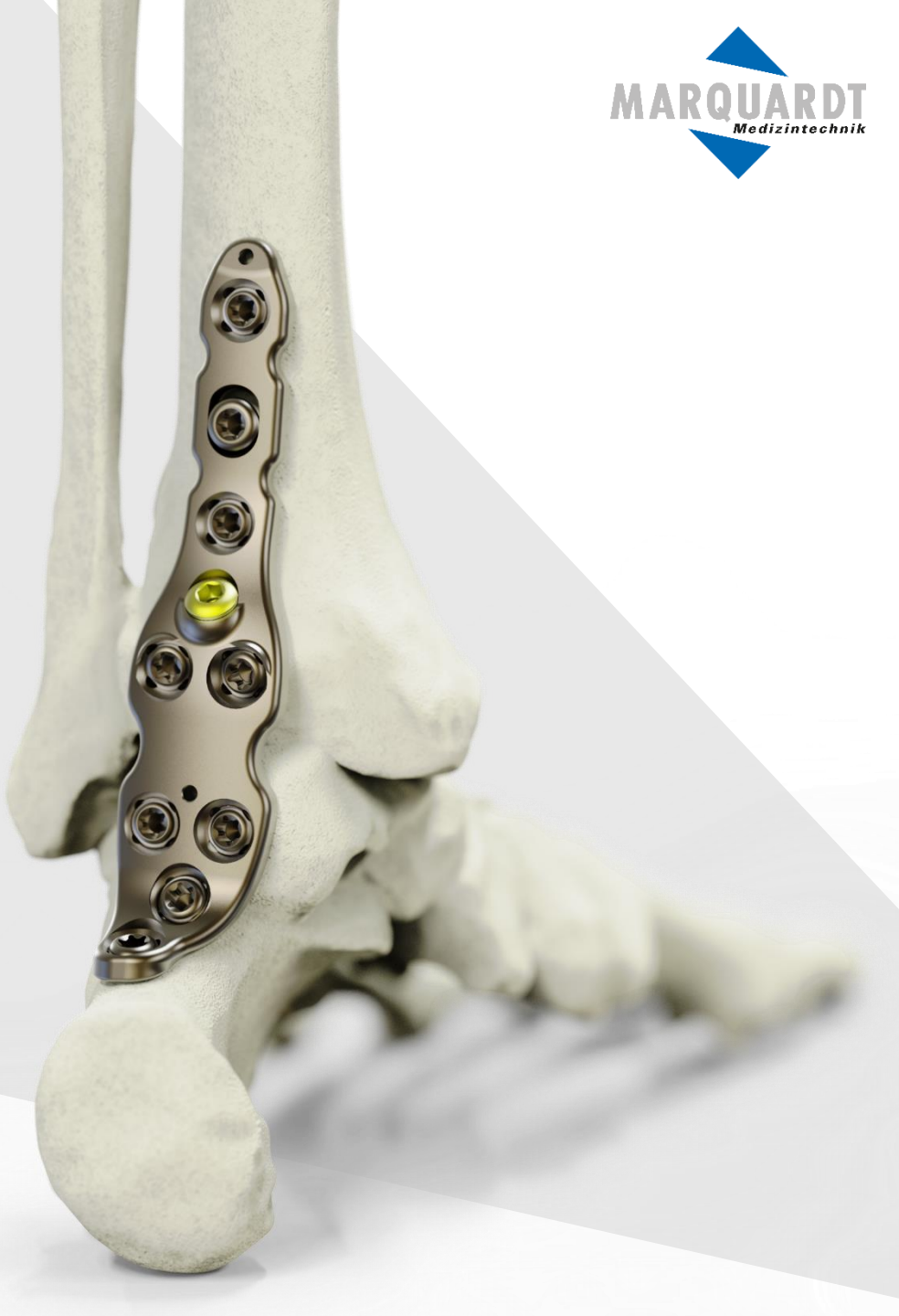

Oberflächenverfahren – Anodisieren Typ II

- Mikroporen und Risse abschwächen
- Ermüdungsfestigkeit + 15%
- Schichthärte + 25%

➔ Integration in Knochengewebe reduzieren

➔ Kaltverschweissung reduzieren

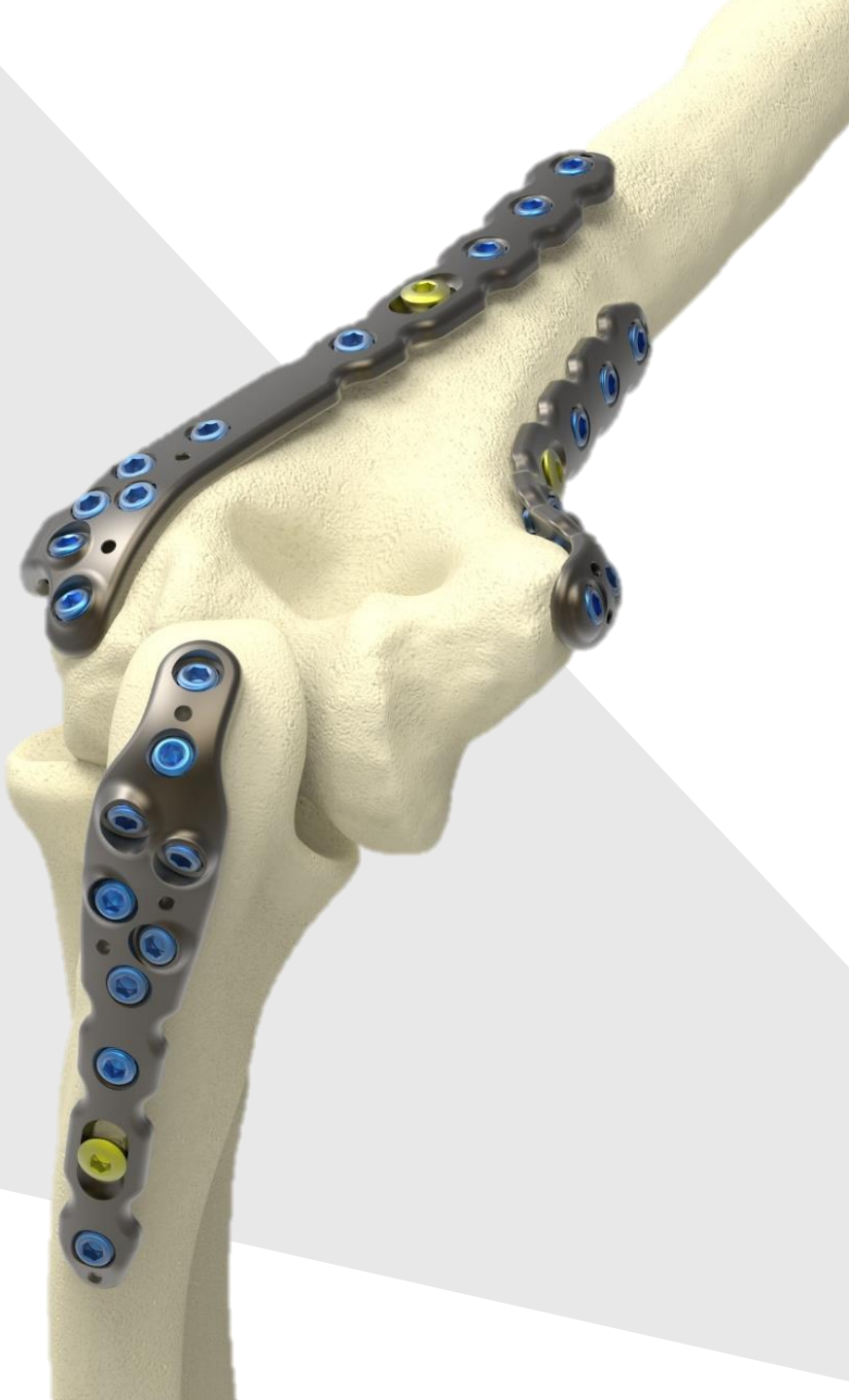

Oberflächenverfahren - Subtraktiv

- Methoden
  - Strahlen
  - Ätzen
  - Laserstrukturieren
- Schicht

  Makro- und Mikroebene
- Ziel

  Schaffung einer Oberflächentopographie für mehr Knochenkontakt mit verbesserter mechanischer Verriegelung

  ➔ Ossäre Integration



Anwendungsbeispiel – TWIN CF

Schraubensystem für Diabetischen Fuß

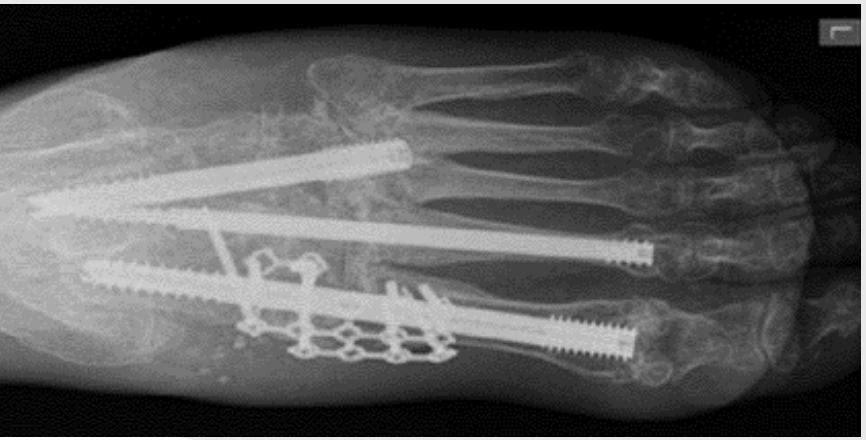

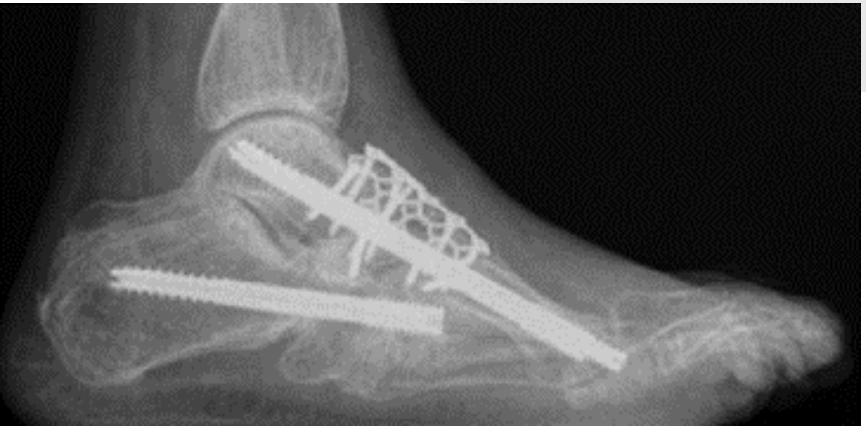

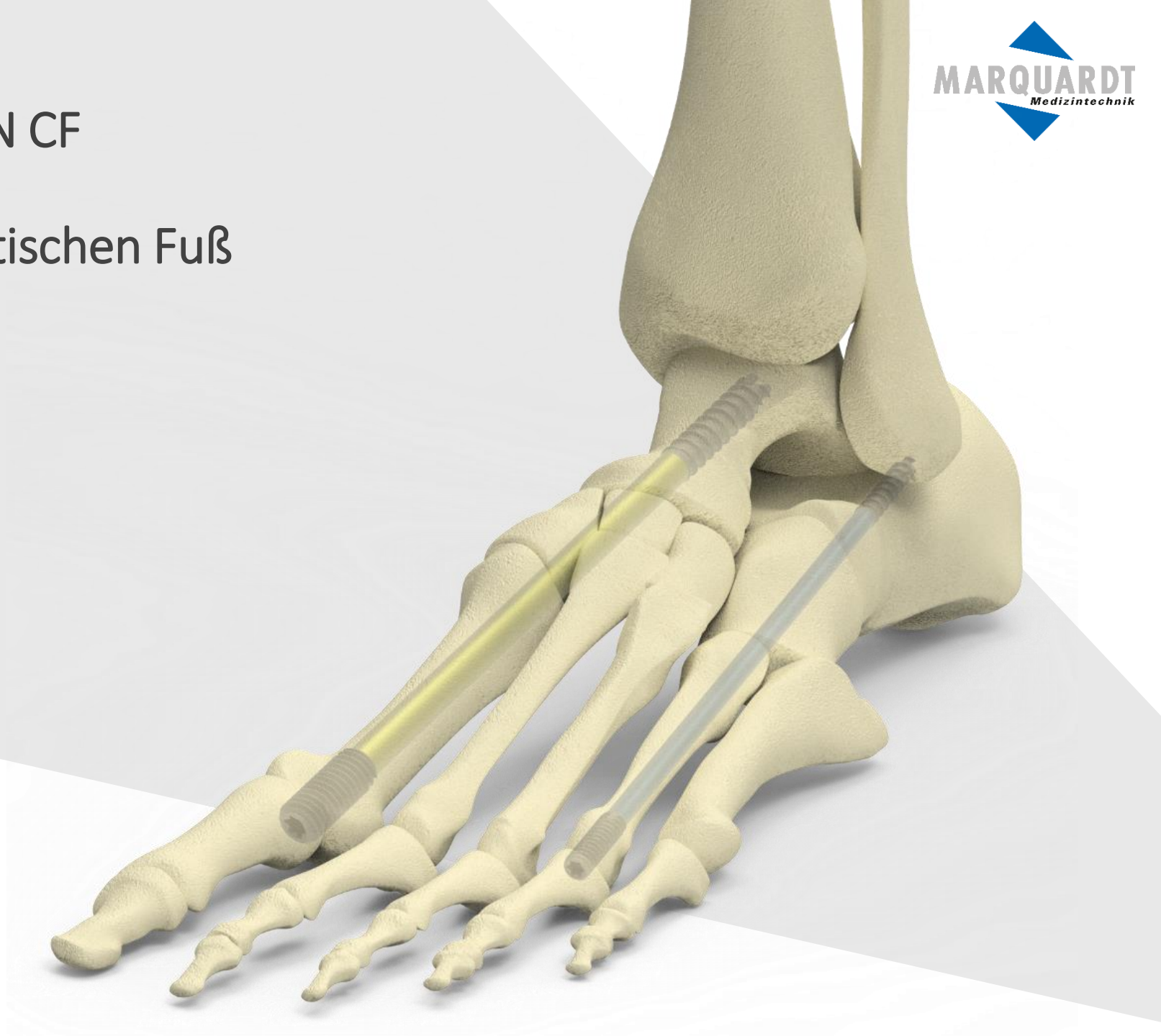

Anwendungsbeispiel – TWIN CF

Oberflächenmodifikationen

Korundgestrahltes Gewinde

Geschliffene Schneiden

Typ III Anodisierung

Zweigängiges Gewinde

Anwendungsbeispiel – TWIN CF

Klinische Ergebnisse

12 Monate Nachuntersuchung:

- ➔ Verbesserte Knochenheilung
- ➔ Gelenkstabilität erhöht
- ➔ Niedrige Dislokationsrate

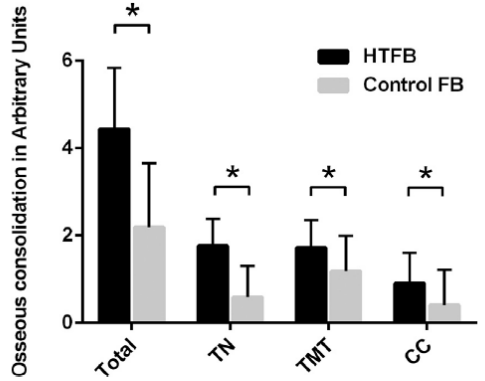

Fig. 5. Scoring of the bony consolidation of the talonavicular (TN), tarsometatarsal (TMT) and calcaneocuboidal (CC) joint as well as the overall summing score of all three joints (maximal score of 6 points, minimal score of 0 points). Fusion area more than 50% was rated with two points in postoperative CT-scans (3 month postoperative), less than 50% with one point and no fusion with zero points. Asterisk indicates statistically significance with $p < 0.016$. HTFB = High-Profile Fusion Bolt Group, CFB = Control Fusion Bolt Group.

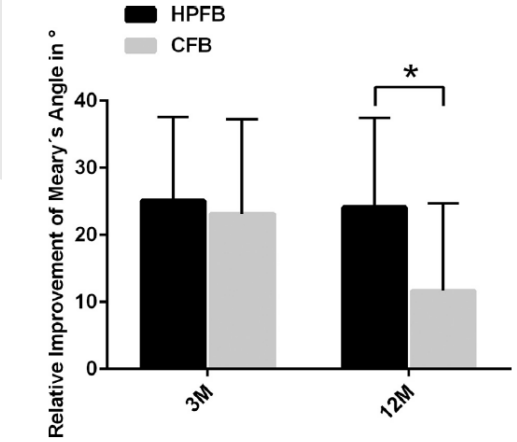

Fig. 6. Improvement of the lateral talometatarsal angle (Meary's Angle) in ° at three month and 12 month follow-up relative to preoperative values. Angles were measured in lateral weight bearing radiographs of the affected foot. Asterisk indicates statistically significance wit $p < 0.01$.

Contents lists available at ScienceDirect

Foot and Ankle Surgery

journal homepage: www.elsevier.com/locate/fas

A high-profile thread with grit-blasted and acid-etched surface reduces loosening of medial column fusion bolt in instable Charcot foot

Alexander T. Mehlhorn[a,b,*], Karl I. Ugland[c], Hubert Hörterer[a], Oliver Gottschalk[a], Norbert Südkamp[b], Markus Walther[a]

[a] Center of Foot and Ankle Surgery, Schön Klinik München Harlaching, Munich, Germany
[b] Department of Orthopedics and Trauma Surgery, Albert-Ludwigs University of Freiburg, Medical Center, Freiburg, Germany
[c] Department of Biosciences, University of Oslo, PB 1066 Blindern, 0316 Oslo, Norway

ARTICLE INFO

Article history:
Received 28 January 2019
Received in revised form 30 March 2019
Accepted 8 August 2019
Available online xxx

Keywords:
Charcot foot
Fusion bolt
Diabetes mellitus

ABSTRACT

Background: Intramedullary fusion bolts (FB) were introduced to stabilize the medial column of the instable Charcot foot (ICF), but complications as bolt loosening or breakage are frequent. We compared the use of a standard FB and a high-profile threaded FB with a grit-blasted surface. We hypothesized that implant related complications occurred less often and osseous consolidation of fusion sites was more distinctive using the latter type of FB.

Methods: Consecutive patients suffering from an ICF were stabilized with a high-profile threaded and surface-modified FB (HTFB) (n = 20) or with a standard FB (n = 20) which was placed into the first ra... Additional bolts and dorsal low-profile plates were applied in every patient. In a retrospectiv... assessment osseous consolidation of the fusion sites was analyzed at 3 month and quantified by CT sca...

Results: Compared to the control group, the HTFB group reached significant higher consolidation after 3 and 12 month longitudinal foot arch collapse and rate of bolt loosening were assessed. At 3 month, No dislocation and a single bolt breakage was observed in the HTFB group after the fourth month while the control group included 3 patients with bolt dislocation at 3 ± 1 month and 5 patients with bo... breakage at 6 ± 1.8 month. Compared to preoperative values, the improvement of Meary's angle aft... one-year was significant higher in the HTFB group (23.4° ± 14) than in controls (11.7° ± 13).

Conclusions: Modification of bolt design improves the stability of the medial column: A higher rate of fosseo... consolidation of the medial column leads to lower rate of bolt dislocation/breakage and finally ... permanently erected longitudinal foot arch. Initially disappointing results following medial colum... stabilization with fusion bolts can be rejected by modifications of bolt design and its technical applicatio...

© 2019 European Foot and Ankle Society. Published by Elsevier Ltd. All rights reserve...

Introduction

Charcot neuropathic osteoarthropathy results in a collapse of the longitudinal arch and breakdown of the foot leading to either recurrent ulcers or strong pain while walking [1]. Conservative treatment of the instable foot includes total contact casting but is associated with the risk of longitudinal foot arch collapse and an extended treatment period. Thus, operative correction with external or internal fixation of the neuropathic foot was introduced as alternative [2,3]. A recent concept of medial column stabilization consists in retrograde intramedullary implantation of a fusion bolt from the first metatarsal head to the talar body [4,5]. Several case-control studies reported many adverse events using midfo... fusion bolt as a single implant. A moderate rate of bone healin... following midfoot arthrodesis suggested a too loose fixation ... arthrodesis [2]. Therefore, other concepts for a more stable fixatio... and a better osseous consolidation were developed. Mid fo... arthrodesis sites were augmented with cancellous bone from th... iliac crest or proximal tibia [6]. From the first disappointing resul... it was obvious that the medial column fusion bolt should not b... used in stand-alone technique. In order to increase rotation... stability, additional implants at the medial column and addition... stabilization of the lateral foot column was suggested [7]. Medi... locking plates or screws for strengthening the construct were use... to augment individual or multijoint fusions [8]. To increase th... stability of the midfoot intramedullary beams were introduce... into the second and fifth metatarsal beyond the talonavicular ... calcaneocuboidal joint. Despite these precautions, up to 60% of th... patients obtained a dislocation or breakage of the midfoot fusio...

* Corresponding author at: Centre of Foot and Ankle Surgery, Schönklinik München Harlaching, Harlachingerstrasse 55, 81549 München, Germany.
E-mail address: amehlhorn@schoen-kliniken.de (A.T. Mehlhorn).

https://doi.org/10.1016/j.fas.2019.08.004

Anwendungsbeispiel – TWIN CF

Klinische Ergebnisse

12 Monate Nachuntersuchung:

- ➔ Verbesserte Knochenheilung
- ➔ Gelenkstabilität erhöht
- ➔ Niedrige Dislokationsrate

- ➔ Neuer Therapieansatz ermöglicht

Conclusions: Modification of bolt design improves the stability of the medial column: A higher rate of osseous consolidation of the medial column leads to lower rate of bolt dislocation/breakage and finally to permanently erected longitudinal foot arch. Initially disappointing results following medial column stabilization with fusion bolts can be rejected by modifications of bolt design and its technical application.

© 2019 European Foot and Ankle Society. Published by Elsevier Ltd. All rights reserved.

Contents lists available at ScienceDirect

Foot and Ankle Surgery

journal homepage: www.elsevier.com/locate/fas

A high-profile thread with grit-blasted and acid-etched surface reduces loosening of medial column fusion bolt in instable Charcot foot

Alexander T. Mehlhorn[a,b,*], Karl I. Ugland[c], Hubert Hörterer[a], Oliver Gottschalk[a], Norbert Südkamp[b], Markus Walther[a]

[a] Center of Foot and Ankle Surgery, Schön Klinik München Harlaching, Munich, Germany
[b] Department of Orthopedics and Trauma Surgery, Albert-Ludwigs University of Freiburg, Medical Center, Freiburg, Germany
[c] Department of Biosciences, University of Oslo, PB 1066 Blindern, 0316 Oslo, Norway

ARTICLE INFO

Article history:
Received 28 January 2019
Received in revised form 30 March 2019
Accepted 8 August 2019
Available online xxx

Keywords:
Charcot foot
Fusion bolt
Diabetes mellitus

ABSTRACT

Background: Intramedullary fusion bolts (FB) were introduced to stabilize the medial column of th instable Charcot foot (ICF), but complications as bolt loosening or breakage are frequent. We compare the use of a standard FB and a high-profile threaded FB with a grit-blasted surface. We hypothesized th implant related complications occurred less often and osseous consolidation of fusion sites was mo distinctive using the latter type of FB.
Methods: Consecutive patients suffering from an ICF were stabilized with a high-profile threaded ar surface-modified FB (HTFB) (n = 20) or with a standard FB (n = 20) which was placed into the first ra Additional bolts and dorsal low-profile plates were applied in every patient. In a retrospectiv assessment osseous consolidation of the fusion sites was analyzed at 3 month and quantified by CT sca At 3 and 12 month longitudinal foot arch collapse and rate of bolt loosening were assessed.
Results: Compared to the control group, the HTFB group reached significant higher consolidation after month. No dislocation and a single bolt breakage was observed in the HTFB group after the fourth mont while the control group included 3 patients with bolt dislocation at 3 ± 1 month and 5 patients with bo breakage at 6 ± 1.8 month. Compared to preoperative values, the improvement of Meary's angle aft one-year was significant higher in the HTFB group (23.4° ± 14) than in controls (11.7° ± 13).
Conclusions: Modification of bolt design improves the stability of the medial column: A higher rate of osseou consolidation of the medial column leads to lower rate of bolt dislocation/breakage and finally permanently erected longitudinal foot arch. Initially disappointing results following medial colum stabilization with fusion bolts can be rejected by modifications of bolt design and its technical applicatio

© 2019 European Foot and Ankle Society. Published by Elsevier Ltd. All rights reserve

Introduction

Charcot neuropathic osteoarthropathy results in a collapse of the longitudinal arch and breakdown of the foot leading to either current ulcers or strong pain while walking [1]. Conservative treatment of the instable foot includes total contact casting but is associated with the risk of longitudinal foot arch collapse and an extended treatment period. Thus, operative correction with external or internal fixation of the neuropathic foot was introduced as alternative [2,3]. A recent concept of medial column stabilization consists in retrograde intramedullary implantation of a fusion bolt from the first metatarsal head to the talar body [4,5]. Several case-control studies reported many adverse events using midfo fusion bolt as a single implant. A moderate rate of bone healin following midfoot arthrodesis suggested a too loose fixation arthrodesis [2]. Therefore, other concepts for a more stable fixatio and a better osseous consolidation were developed. Mid fo arthrodesis sites were augmented with cancellous bone from th iliac crest or proximal tibia [6]. From the first disappointing resul it was obvious that the medial column fusion bolt should not b used in stand-alone technique. In order to increase rotation stability, additional implants at the medial column and addition stabilization of the lateral foot column was suggested [7]. Medi locking plates or screws for strengthening the construct were use to augment individual or multijoint fusions [8]. To increase th stability of the midfoot intramedullary beams were introduce into the second and fifth metatarsal beyond the talonavicular calcaneocuboidal joint. Despite these precautions, up to 60% of th patients obtained a dislocation or breakage of the midfoot fusio

* Corresponding author at: Centre of Foot and Ankle Surgery, Schönklinik München Harlaching, Harlachingerstrasse 55, 81549 München, Germany.
E-mail address: amehlhorn@schoen-kliniken.de (A.T. Mehlhorn).

https://doi.org/10.1016/j.fas.2019.08.004

Oberflächenverfahren – Additive Verfahren

- Osseointegration - Einwachsverhalten

- Plasmaspray Verfahren **VPS**
  - Poröse Titan Beschichtung auf
    - Metall
    - Keramik
    - Kunststoff (PEEK)



Oberflächenverfahren – Additive Verfahren

- Osseointegration - Einwachsverhalten

- Plasmaspray Verfahren **VPS**
  - Poröse Titan Beschichtung auf
    - Metall
    - Keramik
    - Kunststoff (PEEK)

  - Calciumphosphat / HA-Beschichtung
    - Anpassung Schnittstelle Implantat - Knochen
    - Schnellere Heilungsphase belegt

Oberflächenverfahren – HA Beschichtung

- Elektrochemische HA-Beschichtungen
  - Geringere Schichtdicke
  - → Bioaktive Beschichtung temporär bis Integration
  - Beschichtung bei Raumtemperatur
  - Gleichmäßige Bedeckung ≠ „line of sight“ Prozess
  - Kompositbeschichtungen möglich

Oberflächenverfahren – Infektionsprophylaxe

- Postoperative Infektion = bedeutendste Komplikation

- Antibakterielle Oberfläche
  - Antibiotika → lokal
  - Silberionen

- Plasmaspray: Silberionen in HA-Beschichtung
- Elektrochemische Verfahren

- Keine etablierten antibakteriellen Implantate

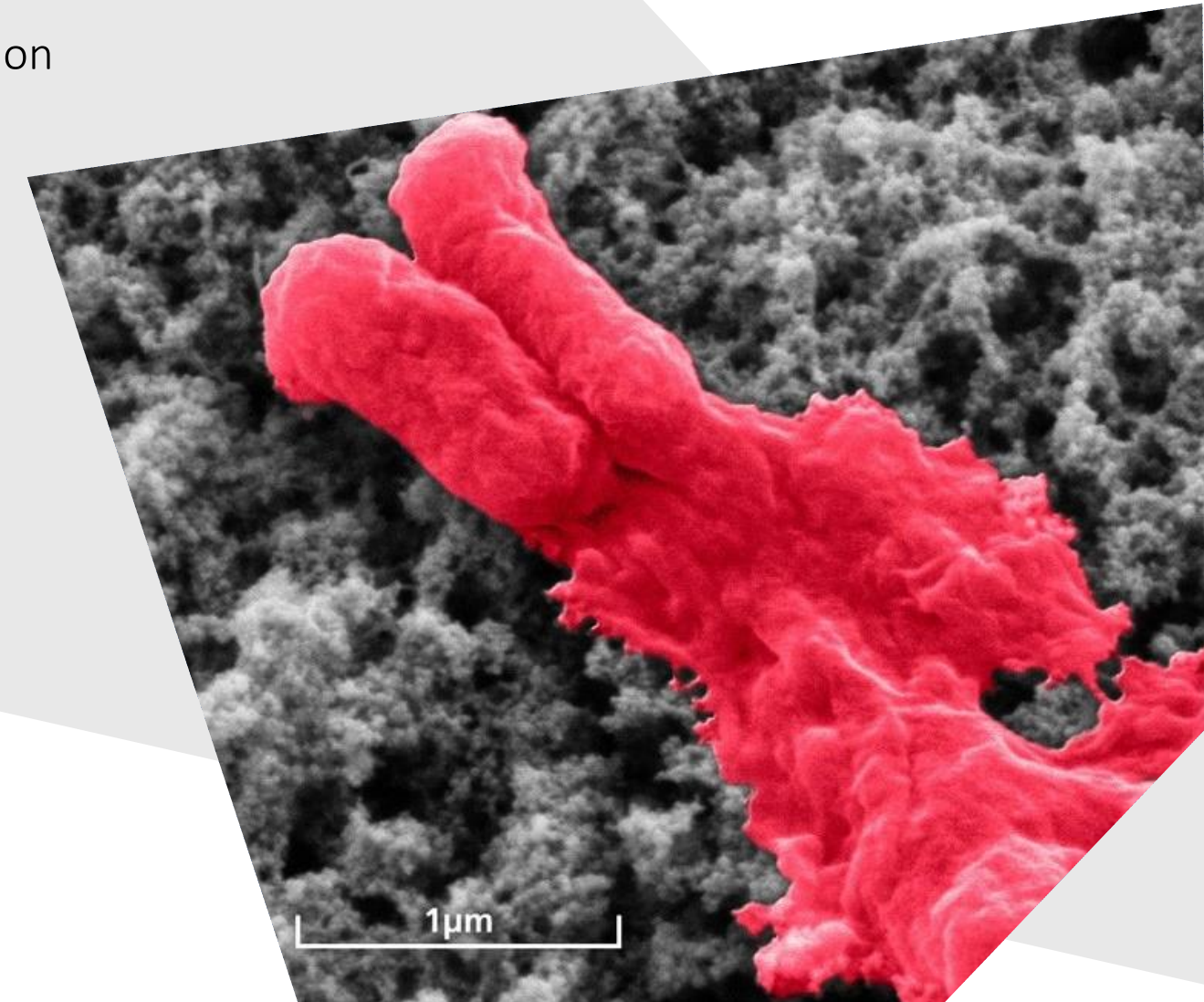

Ausblick– Allgemein

- Untersuchung und Nachbildung der extrazellulären Matrix

➔ Biomaterial nach dem Vorbild der Natur

- Anpassung additiver Verfahren auf die Verarbeitung von biologischen Materialien und Zellen für personalisierte Implantate

- Entwicklung von Biotinten „Knochentinten“ für funktionales Knochengewebe

Ausblick – Marquardt Medizintechnik

Forschungsprojekt in Kooperation mit Fraunhofer-Institut **IMW**

- Kombination aus elektrochemischer Oberflächenmodifizierung mit nanoskaliger Funktionalisierung



Abb. 1: Osteosynthesematerial der Firma Marquardt Medizintechnik GmbH (links), Darstellung einer Porenstruktur nach Oberflächenmodifizierung (Mitte) und nanoskalige Funktionalisierung mit dem Verfahren des Elektrospinnen (rechts)

MARQUARDT
Medizintechnik

VIELEN DANK